A suspicious lump on the head: a case of sinus pericranii

Matthew DeSalvo, Harvard Medical School Year IV
Gillian Lieberman, MD

Matthew DeSalvo, HMSIV
Gillian Lieberman, MD

Outline

- Our patient initial presentation
- Menu of radiologic tests
- Our patient continued
- A brief review of vascular anatomy of the head
- Overview of sinus pericranii
- Our patient conclusion

Matthew DeSalvo, HMSIV
Gillian Lieberman, MD

Our patient: history

- CC: The patient is a 34-year-old gentleman with little past medical history, presenting to reestablish primary care. He has not seen a doctor in over 10 years.

- HPI: He has a lump on his head, which he has had since he was a small child. He reports sustaining physical abuse from family members at a young age. He also reports that this lump seems to get more sweaty and erythematous when his blood pressure rises.

Matthew DeSalvo, HMSIV
Gillian Lieberman, MD

Our patient: history continued

- PMH: Anxiety, hypertension
- Meds: None
- Allergies: Penicillin
- SH: Works as a mechanic. Father of four children. 14 pack years smoking, 1 drink every week, no recreational drug use.
- FH: Seizures, diabetes, hypertension, hyperlipidemia
- ROS: Headaches, chest pain, shoulder pain

Matthew DeSalvo, HMSIV
Gillian Lieberman, MD

Our patient: physical exam

VS: T 98.1, BP 130/90, HR 80s

GENERAL: In no acute distress, well-appearing muscular gentleman.

HEENT: Mucous membranes moist. Pupils equal, round, reactive to light. Oropharynx without erythema or exudates.

NECK: Supple, no lymphadenopathy or thyromegaly.

CARDIAC: Regular rate and rhythm; no murmurs, rubs or gallops. S1 and S2.

PULMONARY: Clear to auscultation bilaterally. No wheezes or rales.

ABDOMEN: Soft, nontender, nondistended, no hepatosplenomegaly appreciated or masses appreciated.

EXTREMITIES: Warm and well perfused, no peripheral edema.

NEURO: A&Ox3, CN2-12 intact, normal motor and sensation, normal reflexes, gait

SKIN: His head exam did reveal a 2 x 3 inch ovular bump about 2 cm in height in the vertex of the skull in the midline, which was nonpulsatile, nonmobile, fixed, fairly soft and mildly tender and nonerythematous or warm without ecchymosis.

Matthew DeSalvo, HMSIV
Gillian Lieberman, MD

Our patient: differential diagnosis

- Our patient has a scalp mass
- Etiologies include:
  - *Infectious: Cellulitis (dissecting), carbuncle, abscess*
  - *Neoplasm: Lipoma, fibroma, hemangioma, angiosarcoma*
  - *Congenital: Meningocele, encephalocele, dermoid cyst, vascular abnormality (e.g. sinus pericranii)*
  - *Anatomic: Exostosis, sebaceous cyst*
  - *Other: Organized chronic hematoma (trauma), ingrown hair*
- What imaging modalities are available to evaluate this lesion?

Matthew DeSalvo, HMSIV
Gillian Lieberman, MD

Outline

- Our patient initial presentation
- Menu of radiologic tests
- Our patient continued
- A brief review of vascular anatomy of the head
- Overview of sinus pericranii
- Our patient conclusion

Matthew DeSalvo, HMSIV
Gillian Lieberman, MD

Menu of radiological tests

- Ultrasound of cranium
  - Quick, inexpensive and good for soft tissue if no air/bone (e.g. scalp)
  - Doppler to assess flow/vascularity
- Radiograph of skull
  - Can identify bony pathology
  - Difficult to visualize this part of cranium in a projectional image; poor soft tissue visualization
- CT Head
  - Good for imaging cortical bone, acute hemorrhage, massive herniation
  - Poor resolution for soft tissue
- MR Head with and without contrast
  - T1 C^- and C^+: best to evaluate brain anatomy and soft tissues and for lesion enhancement
  - T2: excellent for edema and infarction
- Angiography
  - Gold standard for determining vascular anatomy, can intervene, but invasive

Matthew DeSalvo, HMSIV
Gillian Lieberman, MD

Outline

- Our patient initial presentation
- Menu of radiologic tests
- Our patient continued
- A brief review of vascular anatomy of the head
- Overview of sinus pericranii
- Our patient conclusion

Matthew DeSalvo, HMSIV
Gillian Lieberman, MD

Our patient: next step

A scalp ultrasound was obtained for our patient.

Beth Israel Deaconess Medical Center
Matthew DeSalvo, HMSIV
Gillian Lieberman, MD

Our patient: Cranial ultrasound

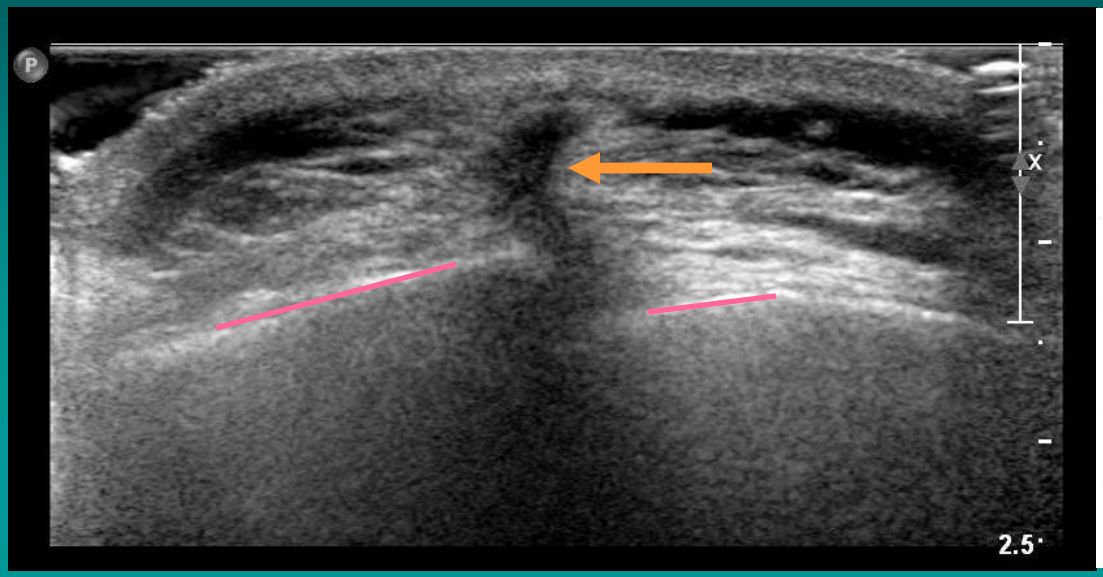

Ultrasound cranial vertex, sagittal view

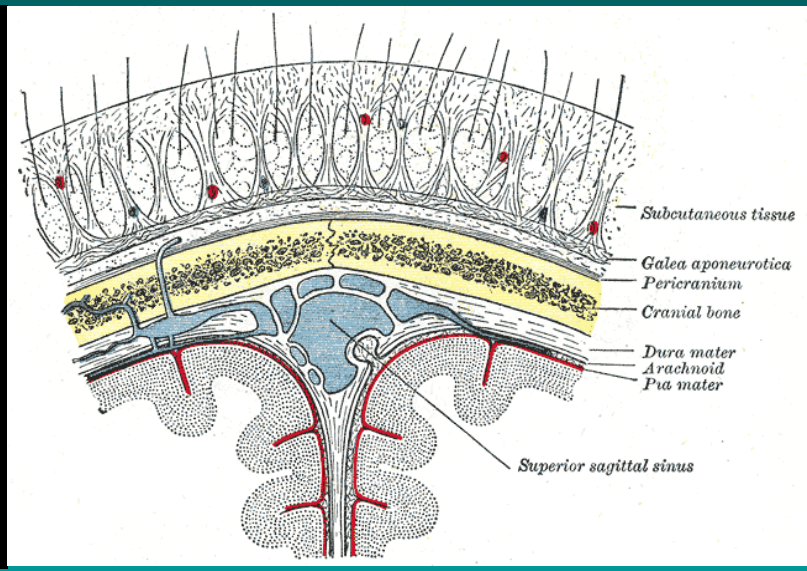

http://upload.wikimedia.org/wikipedia/commons/e/ef/Gray1196.png

Gray's Anatomy

A focal defect in the profile of the cranial cortex, and at the site of an apparent stepoff, with a serpiginous hypo-to-anechoic structure extending to within 3 mm of the skin surface.

Images from BIDMC PACS

Matthew DeSalvo, HMSIV
Gillian Lieberman, MD

Our pt: Cranial ultrasound cont'd

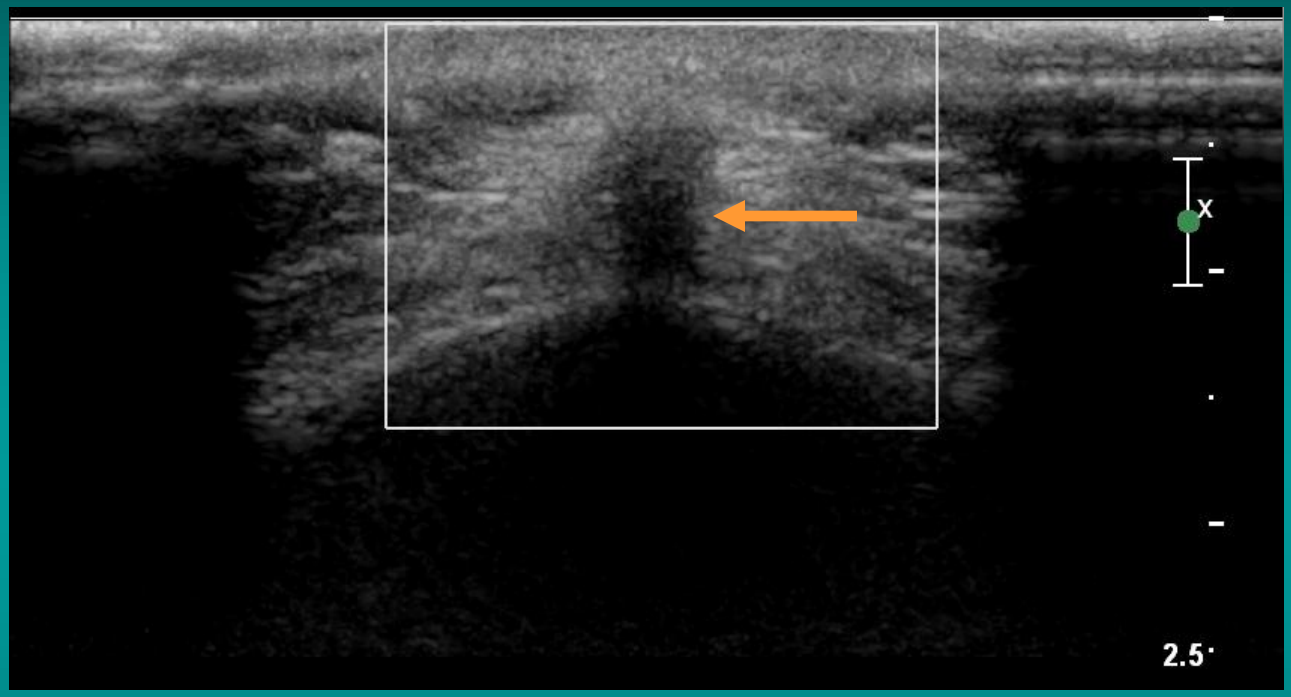

Doppler ultrasound cranial vertex, transverse view

Seen again on transverse doppler ultrasound, this structure does not appear to display internal flow.

Images from BIDMC PACS

Matthew DeSalvo, HMSIV
Gillian Lieberman, MD

Our pt: summary of ultrasound findings

- Our patient has a serpiginous structure that appears to extend to the base of a cranial stepoff and therefore continuity with intracranial structures is possible.

- Given the imaging characteristics of this lesion on ultrasound, what is our differential diagnosis at this point?
  - Meningocele
  - Encephalocele
  - Sinus pericranii (likely thrombosed)

How can we distinguish these various entities radiologically?

Matthew DeSalvo, HMSIV
Gillian Lieberman, MD

Our patient: next step

An MR head with and without intravenous contrast was obtained to further evaluate this abnormality. But first, let's briefly review intracranial venous anatomy.

Matthew DeSalvo, HMSIV
Gillian Lieberman, MD

Outline

- Our patient initial presentation
- Menu of radiologic tests
- Our patient continued
- A brief review of vascular anatomy of the head
- Overview of sinus pericranii
- Our patient conclusion

Beth Israel Deaconess Medical Center
Matthew DeSalvo, HMSIV
Gillian Lieberman, MD

Normal intracranial venous anatomy

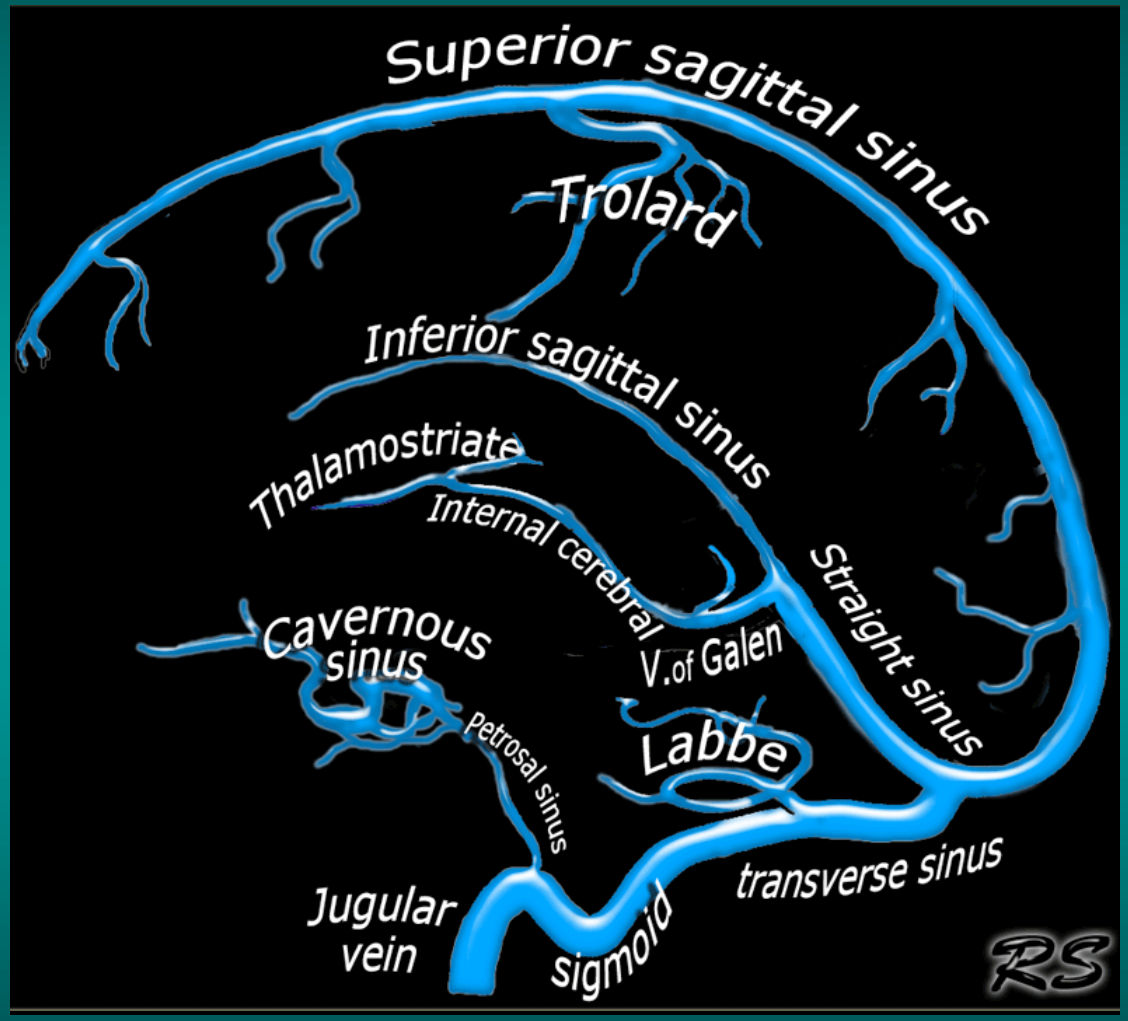

http://www.radiologyassistant.nl/images/4ce832dee302dVENOUS-ANATOMY.png

Illustration of intracranial venous anatomy from lateral view

Beth Israel Deaconess Medical Center
Matthew DeSalvo, HMSIV
Gillian Lieberman, MD

Our patient: MR head

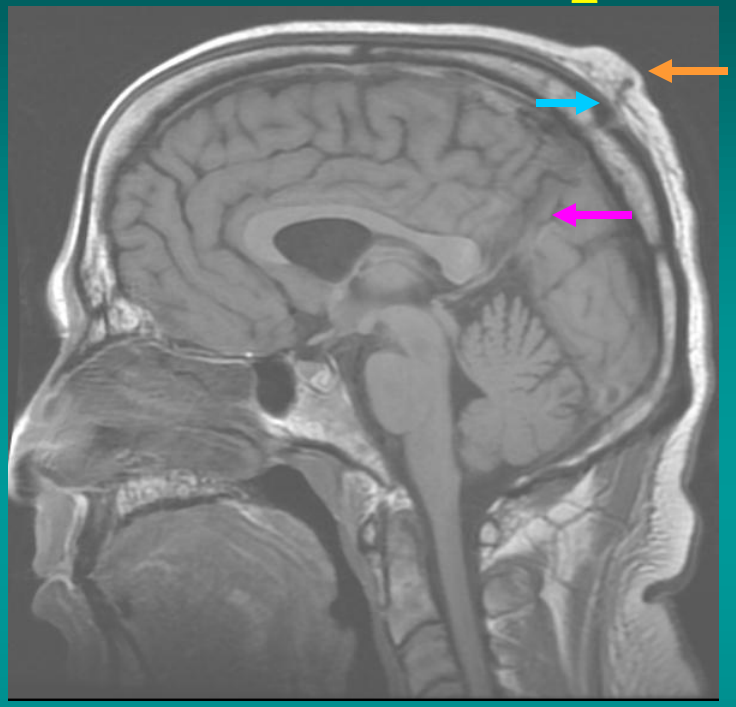

MR head C$^-$ sagittal T1 FLAIR

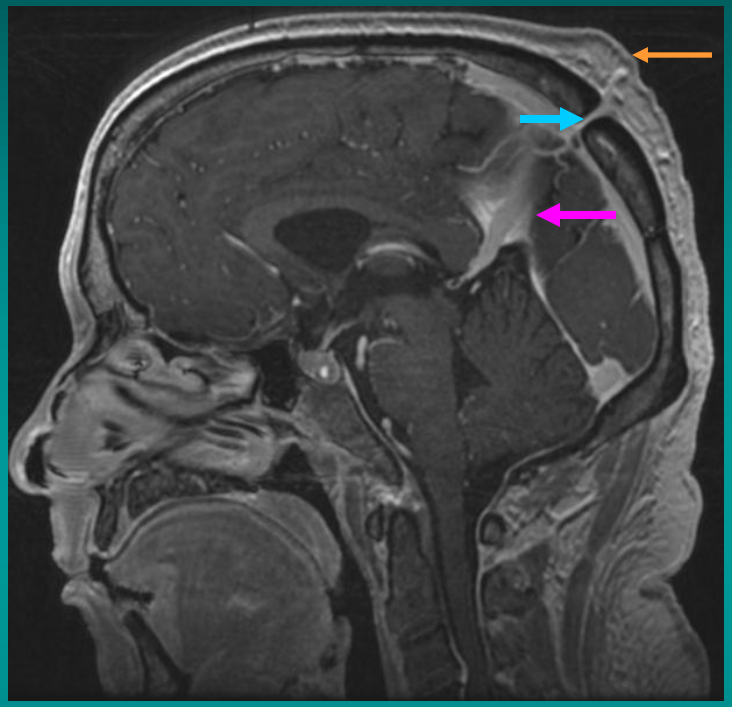

MR head C$^+$ sagittal MP-RAGE

- Soft tissue prominence
- There is a tubular structure, centered within the lesion and extending through the subjacent calvaria communicating with the superior sagittal sinus likely representing sinus pericranii.
- Persistent falcine sinus, an embryologic variant, communicating between the superior sagittal sinus and vein of Galen.

Images from BIDMC PACS

Beth Israel Deaconess Medical Center
Matthew DeSalvo, HMSIV
Gillian Lieberman, MD

Our patient: MR head cont'd

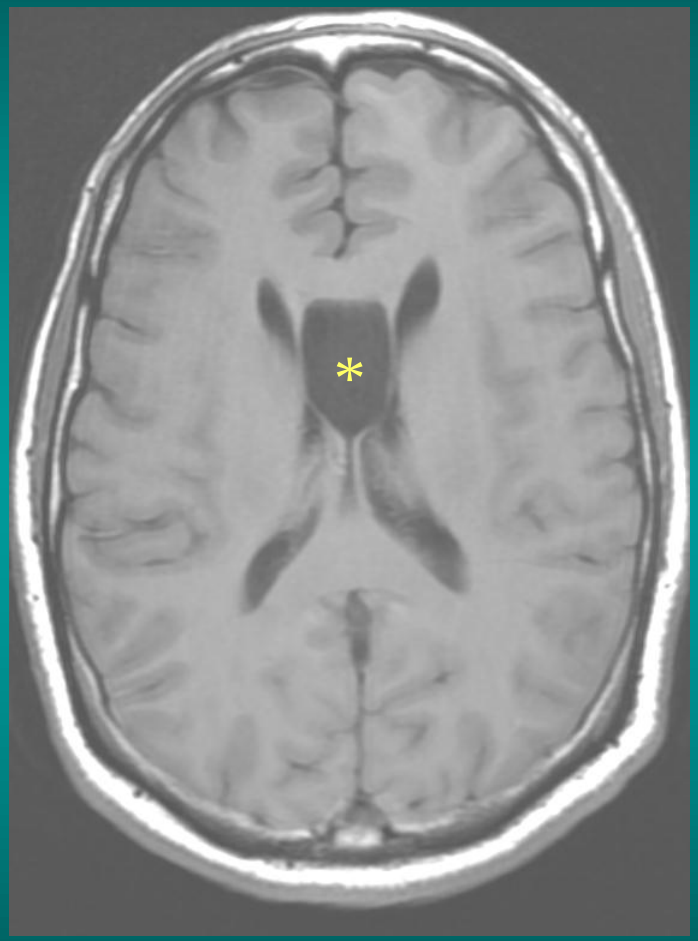

MR head C- axial T1 FLAIR

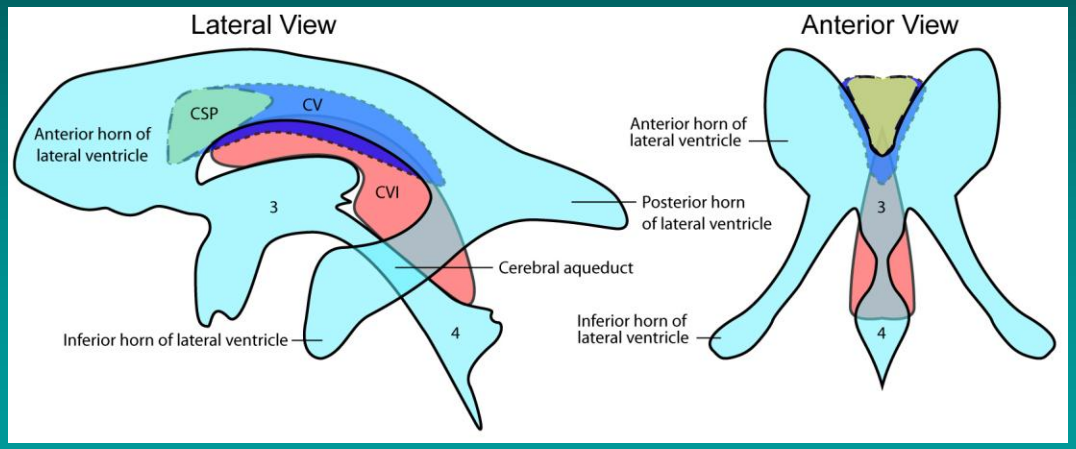

http://upload.wikimedia.org/wikipedia/en/thumb/2/20/Cavum.jpg/800px-Cavum.jpg

Illustration of ventricular anomalies.

CSP=cavum septum pellucidum; CV=cavum vergae; CVI=cavum velum interpositi

Cavum septum pellucidum without cavum vergae is noted. This measures 21mm in diameter and appears ballooned.

Images from BIDMC PACS

Matthew DeSalvo, HMSIV
Gillian Lieberman, MD

Our patient: summary of findings

Our patient has a scalp mass which demonstrates a vascular connection to the superior sagittal sinus, representing sinus pericranii as well as a persistent falcine sinus and cavum septum pellucidum.

Now that our patient has been diagnosed with presumed sinus pericranii, let's learn some basic facts about this condition.

Matthew DeSalvo, HMSIV
Gillian Lieberman, MD

Outline

- Our patient initial presentation
- Menu of radiologic tests
- Our patient continued
- A brief review of vascular anatomy of the head
- Overview of sinus pericranii
- Our patient conclusion

Matthew DeSalvo, HMSIV
Gillian Lieberman, MD

Sinus pericranii: some basic facts

- Sinus pericranii is a rare, usually asymptomatic condition that is characterized by an abnormal communication between the intra- and extracranial venous drainage pathways.
- Sinus pericranii was initially described by Stromeyer in 1850 as a "blood bag on the skull…in connection with the veins of the diploë and through these with the sinuses of the brain."
- Head trauma has been proposed as a possible acquired etiology but its frequent association with other intracranial vascular anomalies, such as dural venous anomalies, suggests that a congenital cause is more likely.
- SP typically presents in younger patients: the average age was 20 years in one small case series.
- The condition occurs with equal incidence in male and female patients, although males are more often involved in posttraumatic cases.
- In most patients SP occurs along the midline. One series found prevalences to be 40% frontal, 34% parietal, 23% occipital, and 4% temporal.
- Clinical symptoms of SP are often mild, including headache, sensations of pressure or fullness, vertigo, or localized pain.

Sinus pericranii: treatment

- Treatment of SP has mainly been recommended for cosmetics, prevention of hemorrhage, and the risk of air embolism.
- Surgery is the established method of treatment, with the first recognized successful surgery for SP reported in 1902.
- Recent case reports show that SP can be treated using endovascular embolization with onyx.
- Other studies have demonstrated that disconnection of emissary veins alone has may be adequate and bone wax can be used to close cranial defects.

Matthew DeSalvo, HMSIV
Gillian Lieberman, MD

Outline

- Our patient initial presentation
- Menu of radiologic tests
- Our patient continued
- A brief review of vascular anatomy of the head
- Overview of sinus pericranii
- Our patient conclusion

Matthew DeSalvo, HMSIV
Gillian Lieberman, MD

Our patient: continued course

Our patient was referred to neurosurgery and underwent carotid/cerebral angiography to further characterize his vascular anatomy.

Beth Israel Deaconess Medical Center
Matthew DeSalvo, HMSIV
Gillian Lieberman, MD

Our patient: angiography

RICA angiogram, venous phase frontal view

RICA angiogram, venous phase lateral view

Carotid angiography demonstrates good arterial and venous opacification of vasculature without angiographic evidence of venous communication between the superior sagittal sinus and the scalp swelling even during Valsalva maneuver.

Images from BIDMC PACS

Matthew DeSalvo, HMSIV
Gillian Lieberman, MD

Our patient: conclusion

Because angiography failed to demonstrate flow of contrast between the intra- and extracranial venous systems, our patient went on to be treated conservatively with pain medication to manage headaches and will be seen for further follow-up.

Summary

- Sinus pericranii is a rare condition defined as an anomalous vascular connection between intracranial and extracranial venous drainage systems.
- The etiology is unknown but both congenital and posttraumatic etiologies have been proposed.
- Treatment is primarily surgical and is indicated due to cosmesis, hemorrhage and air embolism.
- Newer minimally invasive endovascular approaches have been reported to treat this condition as well.

Acknowledgements

Thanks to:

Dr. Tamuna Chadashvili

Dr. Douglas Teich

Dr. Gillian Lieberman

Claire Odom

References

- Buxton N and Vloeberghs M. Sinus pericranii. Report of a case and review of the literature. *Pediatr Neurosurg*. 1999 Feb; 30(2):96-9.
- Rangel-Castilla L, Krishna C, Klucznik R et al. Endovascular embolization with Onyx in the management of sinus pericranii: a case report. *Neurosurg Focus*. 2009 Nov;27(5):E13.
- San Millan Ruiz D and Gailloud P. Cerebral developmental venous anomalies. *Childs Nerv Syst*. 2010 Oct;26(10):1395-406.
- Shue M, Fauteux G, Chang H et al. Sinus pericranii: dermatologic considerations and literature review. *J Am Acad Dermatol*. 2002 Jun;46(6):934-41.
- Vinas FC, Valenzuela S and Zuleta A. Literature review: sinus pericranii. *Neurol Res*. 1994 Dev; 16(6):471-4.