Beth Israel Deaconess Medical Center

Samuel Kim, HMSIII
Gillian Lieberman, MD

April 23rd, 2013

Finding the Great Mimicker: Pheochromocytoma

Samuel Kim, Harvard Medical School Year III

Gillian Lieberman, MD



Samuel Kim, HMSIII
Gillian Lieberman, MD

Brief Overview

- Index patient's presentation
- CT, Ultrasound, MRI images from patient
- Clinical background on pheochromocytoma
- Key imaging features for adrenal tumors/pheochromocytoma
- Quiz
- References
- Supplemental Slides (Biochemistry, Ultrasound Imaging, Pathology)

Samuel Kim, HMSIII
Gillian Lieberman, MD

Part I: Our Patient's Presentation

Middle aged woman with history of membranous nephropathy, aortic regurgitation, and hypertension who underwent CT Abdomen/Pelvis evaluation for recurrent renal calculus. An incidental adrenal lesion was found. Patient denied symptoms of palpitations, headaches, hypertension, or diaphoresis at this time.

- No known family of endocrine problems.

Beth Israel Deaconess Medical Center
Samuel Kim, HMSIII
Gillian Lieberman, MD

Our Patient: Adrenal Mass on CT

Our patient's imaging

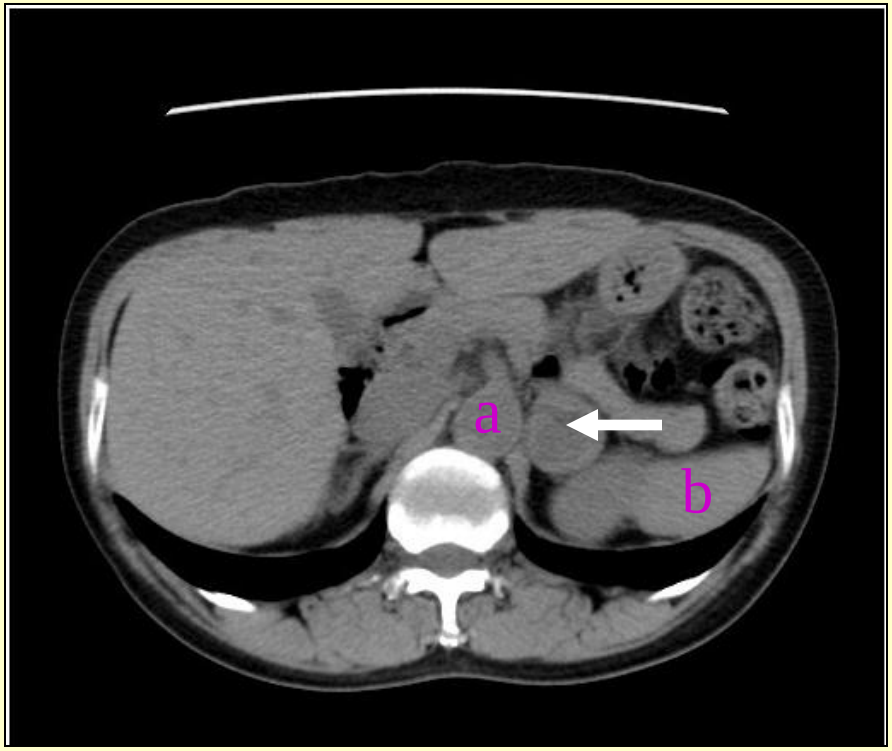

Axial noncontrast CT imaging demonstrating a 2.7x2.7cm left adrenal mass measuring **16 HU unit** (white arrow), "consistent with left adrenal adenoma".
a-aorta, b-spleen

Image from PACS, BIDMC

*Patient underwent CT scan of chest for evaluation of pulmonary nodule the following year and the adrenal lesion was found to be stable without significant change

Samuel Kim, HMSIII
Gillian Lieberman, MD

Our Patient: Adrenal Lesion on Ultrasound 1 year later

Our patient's imaging

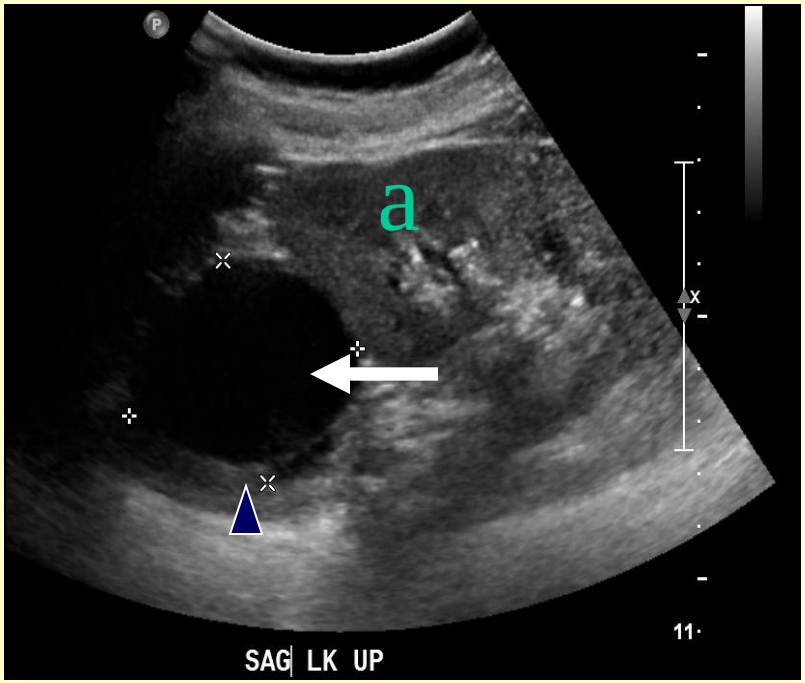

Image from PACS, BIDMC

Patient subsequently underwent renal ultrasound for follow up evaluation of stones. Results consistent with a "complex, largely cystic, left adrenal lesion measuring 4.9cm". Sagittal ultrasound shows adrenal lesion with anechoic central component (white arrow) with a **hypoechogenic peripheral rim** measuring 4.9cm, just superior to the left **kidney**.

*At this time, patient started to complain of loss of 10lbs within a year, occasional chest pain when lying down at night, increased anxiety and sweating. Physical exam, positive for orthostatic hypotension. Systolic blood pressures have been somewhat elevated in the 140s.

Beth Israel Deaconess Medical Center
Samuel Kim, HMSIII
Gillian Lieberman, MD

Our Patient: Adrenal Lesion on Axial MRI

Our patient's imaging: Given concern on patient's ultrasound, patient underwent MRI evaluation. Imaging revealed 4.5x4.3cm left adrenal mass with internal hemorrhage and an associated avidly enhancing wall consistent with a cystic adrenal tumor like pheochromocytoma.

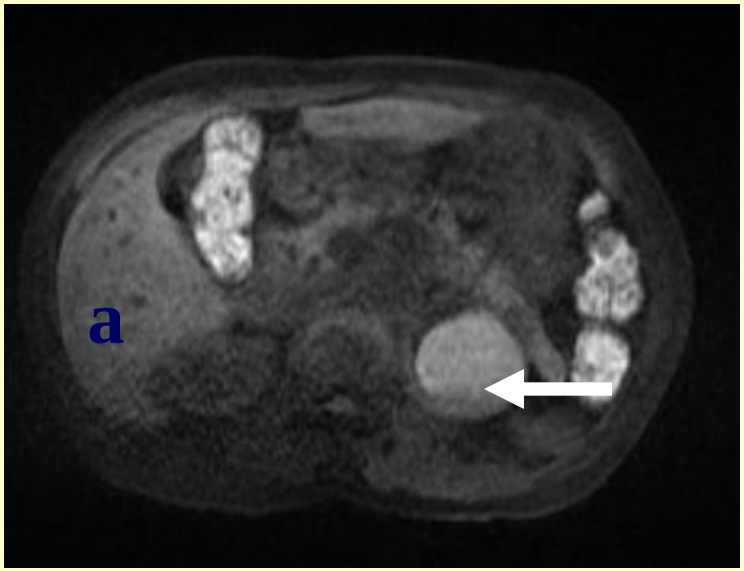

Axial T1 weighted non-contrast image demonstrating a 4.5x4.3cm predominantly hyperintense cystic lesion in the left adrenal gland. Hyperintensity most consistent with hemorrhage.
a-liver

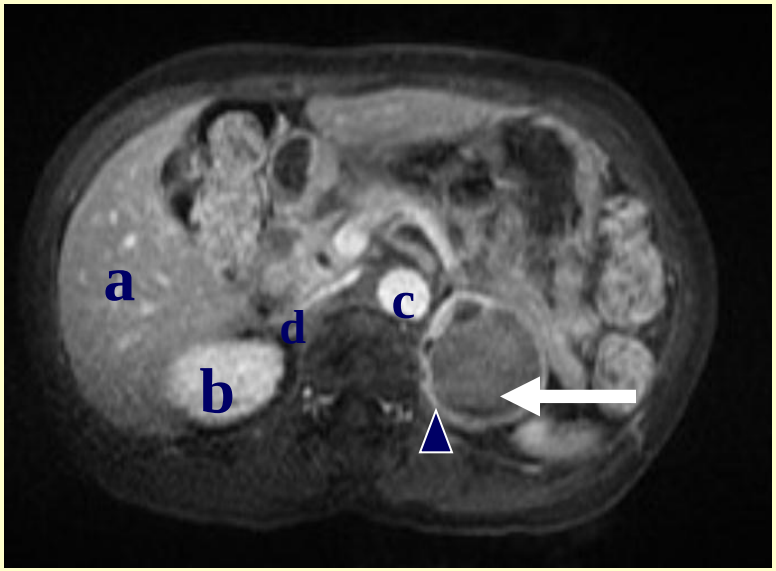

Post-contrast administration demonstrates an enhancing wall with no central enhancement in the left adrenal lesion (white arrow).
a-liver, b-kidney, c-aorta, d- right adrenal triangle-enhancing rim, consistent with solid portion of left adrenal mass.

Image from PACS, BIDMC

Samuel Kim, HMSIII
Gillian Lieberman, MD

Brief Reminder

Hyperintensity on T1W MRI, differential:

- Lipid
- Blood
- Gadolinium
- Manganese, Magnesium, Copper
- Melanin
- Calcium
- Protein
- Slowly flowing blood
- Paramagnetic Material

Beth Israel Deaconess Medical Center
Samuel Kim, HMSIII
Gillian Lieberman, MD

Our Patient: Adrenal Mass on Coronal MRI

Our patient's imaging

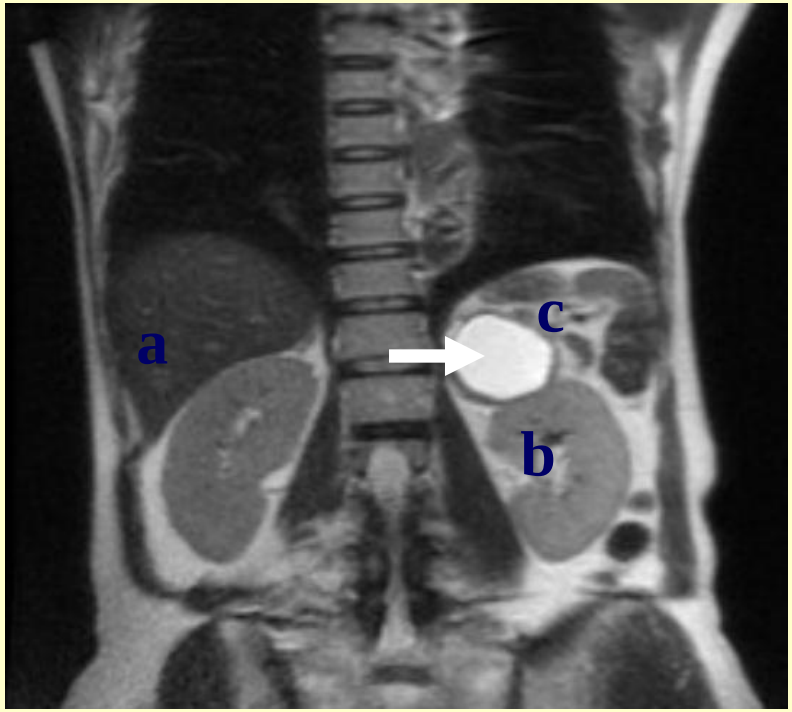

Image from PACS, BIDMC

Coronal T2 weighted image demonstrating hyperintense cystic lesion (white arrow) relative to adrenal parenchyma. Findings consistent with solid mass with internal hemorrhage, predominantly cystic in appearance.
a-liver, b-kidney, c-spleen

*No presence of lipid (fat) on chemical shift MRI

Samuel Kim, HMSIII
Gillian Lieberman, MD

Index Patient Key Points

- CT non contrast – 2.4x2.4cm well circumscribed lesion measuring 16HU
- Ultrasound - complex, largely cystic, left adrenal lesion measuring 4.9cm
- MRI with and without contrast – 4.5x4.3cm hyperintense lesion on T1-weighted imaging (consistent with hemorrhage) and avid enhancement of wall with contrast (solid component). T2-weighted imaging reveals a hyperintense cystic lesion.

Samuel Kim, HMSIII
Gillian Lieberman, MD

Part II: Pheochromocytoma

- Pheochromocytoma is a rare neuro-endocrine tumor arising from the medulla of the adrenal glands or extra-adrenal tissue that secretes catecholamine.
- Group of chromaffin cell neoplasms with different ages of onset, secretory profiles, locations, and potential for malignancy
- Adrenal glands are in the retroperitroneum above the kidneys. Cortex produces cortisol, aldosterone, androgens while medulla produces epinephrine and norepinephrine.

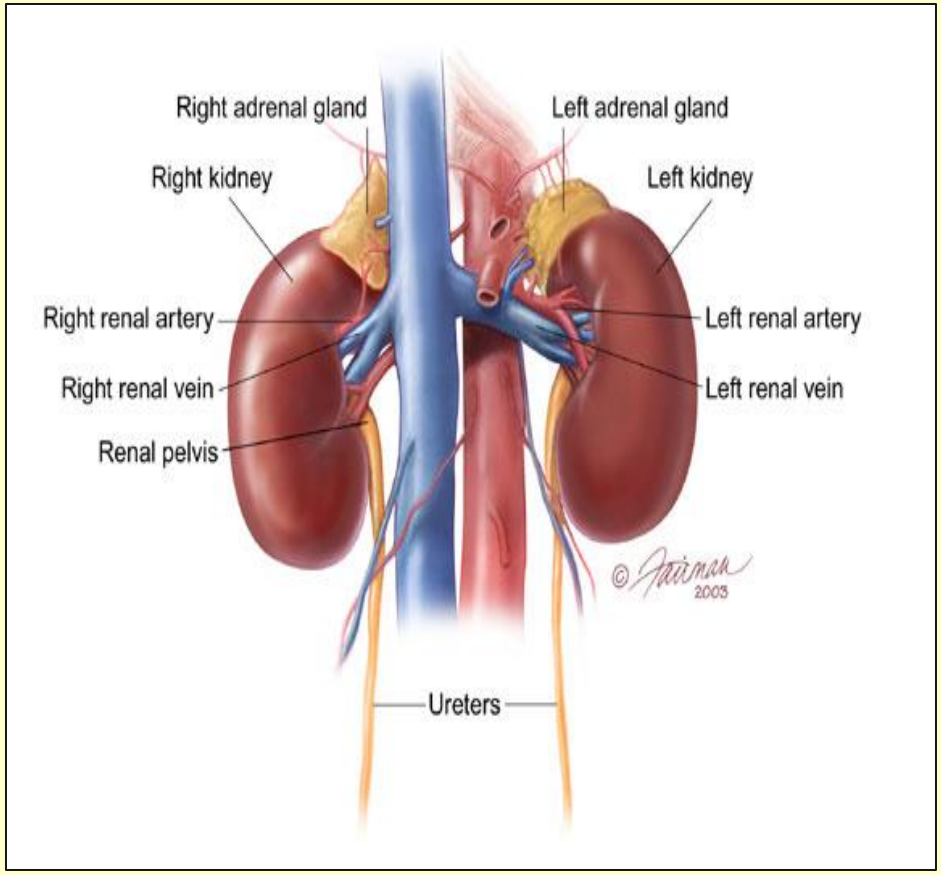

Adrenal gland image from http://www.urologyhealth.org/urology/articles/images/anatomy_AdrenalsKidneys_Anterior.jpg

Samuel Kim, HMSIII
Gillian Lieberman, MD

Pheochromocytoma Epidemiology

- Pheochromocytoma found in about 4.2-6.5% of patients screened for a "incidentaloma"
- 0.3% of secondary causes of hypertension
- Females have a slightly higher incidence with mean age of 44 years for sporadic cases and mean age of 25 for those with genetic predisposition.
- Associated with VHL (Von Hippel-Lindau), MEN (multiple endocrine neoplasia), Neurofibromatosis Type 1

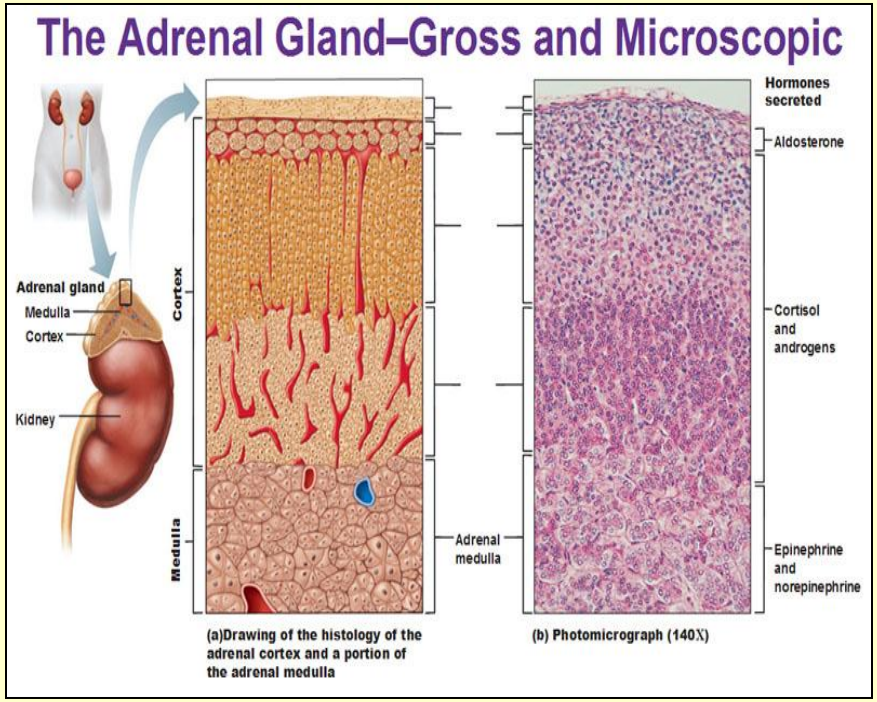

Adrenal gland layer image from http://antranik.org/the-endocrine-system/

Samuel Kim, HMSIII
Gillian Lieberman, MD

Pheochromocytoma: Common Presentations

- Headache, palpitations, and sweating most common. 90% specific for presentation of pheochromocytoma.
- Other symptoms include pallor, nausea, flushing, weight loss, hypertension, orthostatic hypotension, and hyperglycemia
- Most worrisome concern is hypertensive crisis, usually precipitated by certain medications, food, or tumor manipulations.

Hypertension cartoon image from http://www.cartoonstock.com/directory/h/hypertension.asp

Samuel Kim, HMSIII
Gillian Lieberman, MD

Pheochromocytoma: Diagnosis

- Initial screening should include either or both measurements of urinary or plasma metanephrines
- Blood Samples should be drawn under stress free conditions in supine conditions
- In US, liquid chromatography with tandem mass spectrometry generally used for determination of plasma and urinary metanephrines
- Plasma fractionated metanephrines have generally higher sensitivity but lower specificity.

Samuel Kim, HMSIII
Gillian Lieberman, MD

Our Patient's Labs

- On biochemical testing, patient had elevated plasma metanephrines and elevated urinary catecholamines.

Plasma Metanephrine		
Normetanephrine	**4.1 nmol/L**	<0.90
Metanephrine	**8.5 nmol/L**	<0.50
Chromogranin A	**180.0 ng/mL**	(1.90-15.0 ng/mL)
Urinary measurements		
Metanephrine	77 mcg/24h	90-315
Normetanephrine	372 mcg/24h	122-676
Epinephrine	**204 mcg/24h**	2-24
Norepinephrine	**153 mcg/24h**	15-100
Dopamine	188 mcg/24h	52-480

Samuel Kim, HMSIII
Gillian Lieberman, MD

Part III: Menu of Tests for Imaging Adrenal Tumors

- Imaging Features of Different Adrenal Tumors
- ACR Appropriateness Guideline
- CT scan
- Ultrasound
- MRI
- Functional imaging
  - ^{131}I- and ^{123}I-metaiodobenzylguanidine (MIBG)
  - ^{111}-In-pentetreotide
  - PET ligands

Samuel Kim, HMSIII
Gillian Lieberman, MD

Imaging Features of Different Adrenal Masses

- **Adrenal adenomas**: Most common adrenal tumor that is well circumscribed with homogenous lesion found on CT measuring 3cm or less. Usually less than 10HU. Strong contrast enhancement and strong contrast washout.

- **Adrenocortical Carcinoma**: Rare, aggressive tumor usually found in children or older adults. They can be large and invasive. On CT, usually unilateral and solid with necrosis and hemorrhage commonly seen. In washout studies, they tend to retain contrast material. On MRI, Usually hypointense on T1 and hyperintense on T2 compared to liver.

- **Adrenal Neuroblastoma**: Similar to pheochromocytomas in appearance, but more likely to be found in children and generally bigger. Calcifications found in 80-90%.

- **Adrenal Metastasis**: Mets usually bilateral involvement and imaging appearance is more typical of primary tumor. Usually show long washout time. FDG PET useful for confirmation.

- **Adrenal Lymphoma**: Usually bilateral, homogenous, and infiltrates adrenal while maintaining their shape. On CT, usually similar attenuation to muscle. On MRI, usually iso or hypointense on T1 and hyperintense on T2.

- **Pheochromocytoma**: We will discuss on following slides.

Beth Israel Deaconess Medical Center
Samuel Kim, HMSIII
Gillian Lieberman, MD

ACR Appropriateness Guidelines

Variant 1: **No history of malignancy; mass 1-4 cm in diameter. Initial evaluation.**

Radiologic Procedure	Rating	Comments	RRL*
CT abdomen without contrast	8	Presumes that a noncontrast CT has not already been performed and that there are no suspicious imaging features. Should be evaluated by radiologist to determine if contrast administration is needed.	☢☢☢
CT abdomen without and with contrast	8	Indicated if noncontrast CT is not diagnostic or if there are concerning imaging features of malignancy. Delayed imaging obtained to calculate washout.	☢☢☢☢
MRI abdomen without contrast	8	May be helpful when nonenhanced CT is equivocal or if there is suspicious imaging features. Appropriate for patient with iodinated contrast allergy.	O
MIBG	2	Only for suspicion of pheochromocytoma.	☢☢☢
MRI abdomen without and with contrast	2		O
US adrenal gland	1		O
Biopsy adrenal gland	1		Varies
CT abdomen with contrast	1		☢☢☢
X-ray abdomen	1		☢☢
Iodocholesterol scan	1	This agent may be used to detect functionally active adenomas.	☢☢☢☢
FDG-PET/CT skull base to mid-thigh	1		☢☢☢☢

Image From
ACR Appropriateness Guidelines for Incidental Adrenal Mass

Samuel Kim, HMSIII
Gillian Lieberman, MD

ACR Appropriateness Guidelines

Clinical Condition: **Incidentally Discovered Adrenal Mass**

Variant 3: **No history of malignancy; mass >4 cm in diameter. (If not typical for adenoma, myelolipoma, hemorrhage, or simple cyst, consider resection.)**

Radiologic Procedure	Rating	Comments	RRL*
CT abdomen with contrast	8	As part of preoperative staging. Alternative to MRI.	☢☢☢
MRI abdomen without and with contrast	8	As part of preoperative staging. Alternative to CT. See statement regarding contrast in text under "Anticipated Exceptions."	O
FDG-PET/CT skull base to mid-thigh	5	As part of preoperative staging.	☢☢☢☢
MIBG	2	Only for suspicion of pheochromocytoma.	☢☢☢
CT abdomen without and with contrast	2		☢☢☢☢
MRI abdomen without contrast	1		O
US adrenal gland	1		O
CT abdomen without contrast	1		☢☢☢
X-ray abdomen	1		☢☢
Iodocholesterol scan	1	This agent may be used to detect functionally active adenomas.	☢☢☢☢
Biopsy adrenal gland	1		Varies

Image From
ACR Appropriateness Guidelines for Incidental Adrenal Mass

Samuel Kim, HMSIII
Gillian Lieberman, MD

Algorithm for Work Up for Incidentaloma

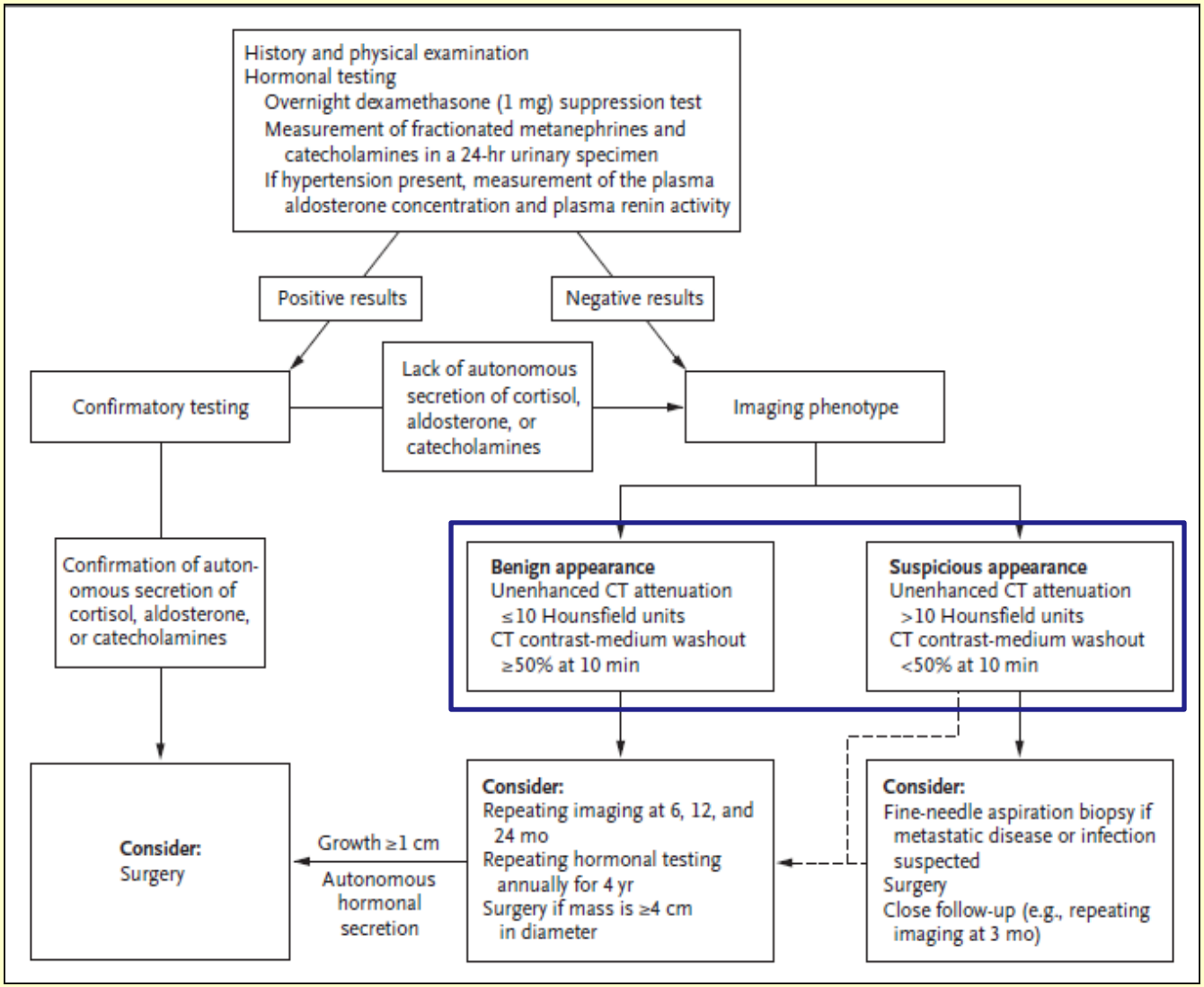

*Focus on the navy box surrounding the difference benign and suspicious appearance of adrenal masses found on CT. These imaging characteristics often dictate appropriate subsequent biochemistry/surgical work up.

From Young, WF. The Incidentally Discovered Adrenal Mass. *New England Journal of Medicine* 2007; 356:601-610

Samuel Kim, HMSIII
Gillian Lieberman, MD

Features of Pheochromocytoma on CT scan

- ***Non-Contrast CT***: Usually presents as low density soft tissue attenuation. 2/3 are solid with 1/3 cystic or complex. **Attenuation values greater than 10 HU almost all the time**. Attenuation less than 10 HU more likely to be adenomas. **CT scan is usually the gold standard for adrenal mass evaluation.**

- However, some pheochromocytoma may contain intracellular fat which can result in lower attenuation than expected. Hemorrhage or calcification can also be found.

- ***Contrast CT***: Homogeneous or variable enhancement however most pheochromocytomas show avid enhancement of solid components.

- Contrast washout typically shows washout less than 40% with a 15-minute delay. Increased washout is more likely to be associated with benign adenoma.

- Larger number of pheochromocytomas show a washout pattern more similar to adenoma than adrenocorticocarcinoma.

Beth Israel Deaconess Medical Center
Samuel Kim, HMSIII
Gillian Lieberman, MD

Companion Patients 1 and 2: Pheochromocytoma on CT

Example Companion 1

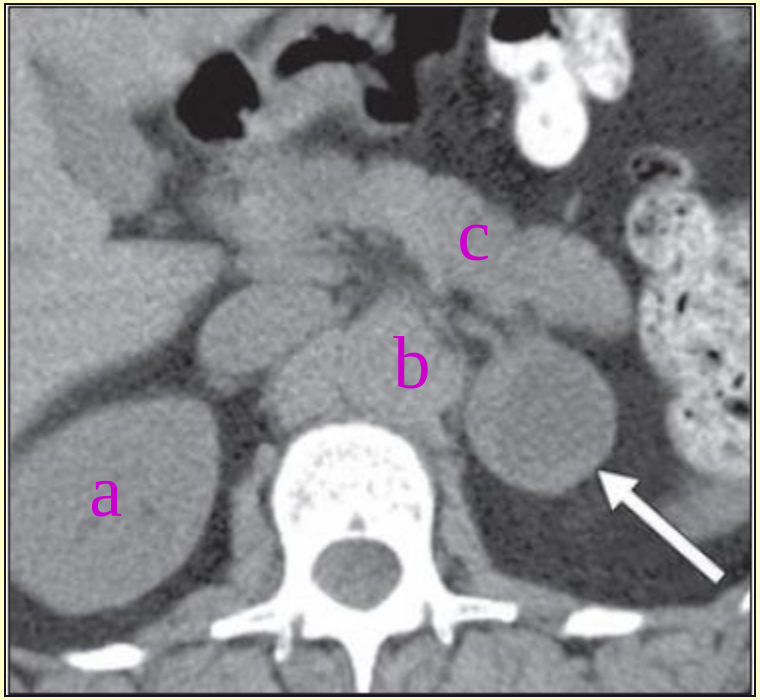

Axial noncontrast CT imaging demonstrating a Low attenuation left adrenal pheochromocytoma with a density of 10HU, similar to adenoma (white arrow). **a-kidney, b-aorta, c-pancreas**

Example Companion 2

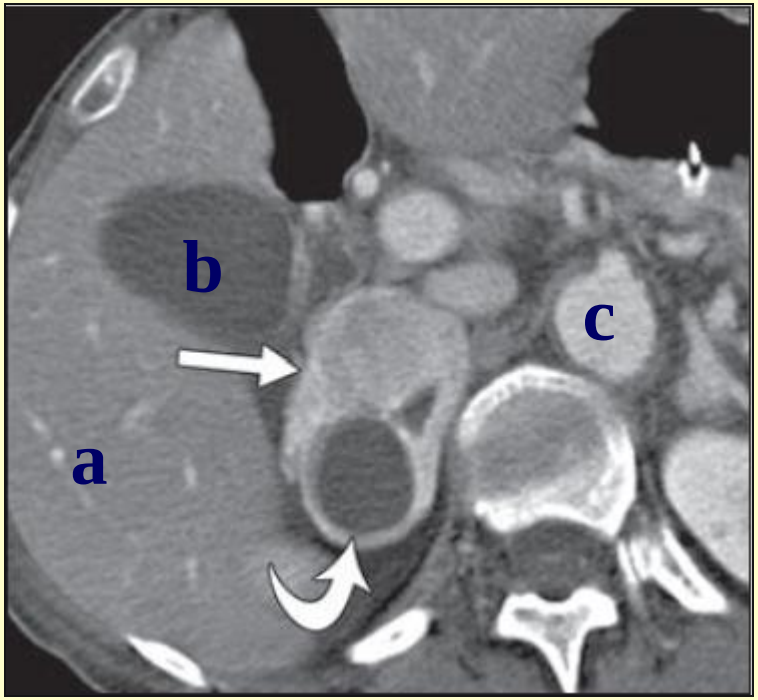

Axial contrast CT imaging demonstrating a Bilobed right pheochromocytoma consisting of solid enhancing component (straight arrow) and cystic posterior component (curved arrow). **a-liver, b-gallbladder, c-aorta**

Images from Leung, K, Stamm, M, Raja, A, Low, G. Pheochromocytoma: The Range of Appearances on Ultrasound, CT, MRI, and Functional Imaging. *AJR* 2013; 200:370-378

Samuel Kim, HMSIII
Gillian Lieberman, MD

Features of Pheochromocytoma on Ultrasound

- In general, pheochromocytomas can mimic many different size and morphologies. Smaller lesions tend to be more homogeneous and larger lesions more heterogeneous.
- On ultrasound, pheochromocytomas often varies ranging from solid to mixed cystic and solid to cystic.
- Ultrasound useful for confirming cystic-necrotic changes within a pheochromocytoma. Cyst can be anechoic or contain debris with posterior acoustic enhancement.

Beth Israel Deaconess Medical Center
Samuel Kim, HMSIII
Gillian Lieberman, MD

Companion Patient 3: Pheochromocytoma on Ultrasound

Example Companion 3

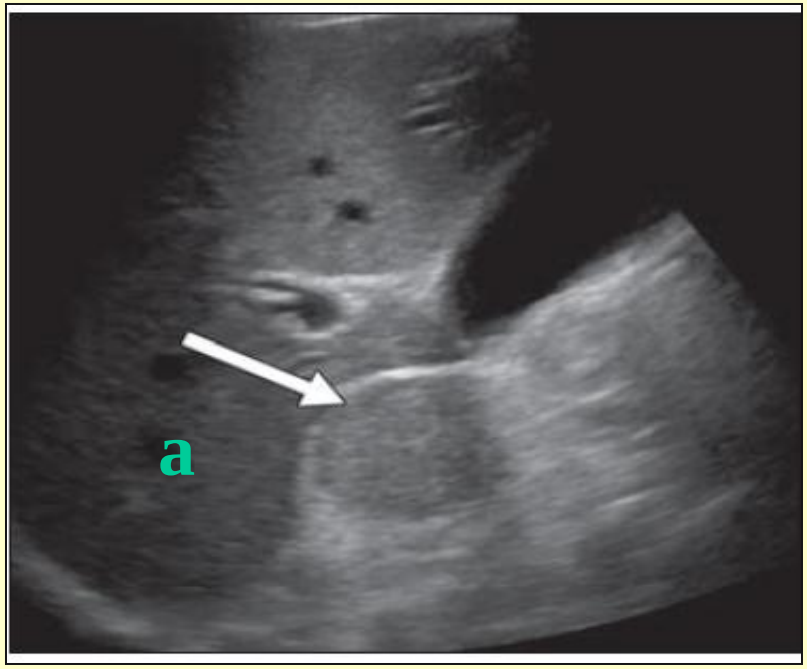

Sagittal ultrasound image showing 4cm solid right adrenal pheochromocytoma that is iso to hyperecohic to the **liver**. (white arrow)

Images from Leung, K, Stamm, M, Raja, A, Low, G. Pheochromocytoma: The Range of Appearances on Ultrasound, CT, MRI, and Functional Imaging. *AJR* 2013; 200:370-378

Samuel Kim, HMSIII
Gillian Lieberman, MD

Features of Pheochromocytoma on MRI

- On T1-weight imaging, pheochromocytomas are usually isointense to muscle and hypointense to liver.
- If necrosis or hemorrhage present, T1 imaging can be variable.
- Classic imaging feature is a “light-bulb” bright lesion on T2-weight imaging, similar to CSF. This is seen in about 11-65% of pheochromocytomas. 35% of cases pheochromocytomas may have low signal intensity on T2-weighted imaging.
- Typically show avid gadolinium enhancement, but can be variable since cystic-necrotic areas will no enhance
- Of note, adrenal adenomas are generally lipid-rich and can be diagnosed on chemical shift MRI. However, pheochromocytoma containing microscopic fat can mimic this appearance as well.

Beth Israel Deaconess Medical Center
Samuel Kim, HMSIII
Gillian Lieberman, MD

Companion Patient 4 and 5: Pheochromocytoma on MRI

Example Companion 4

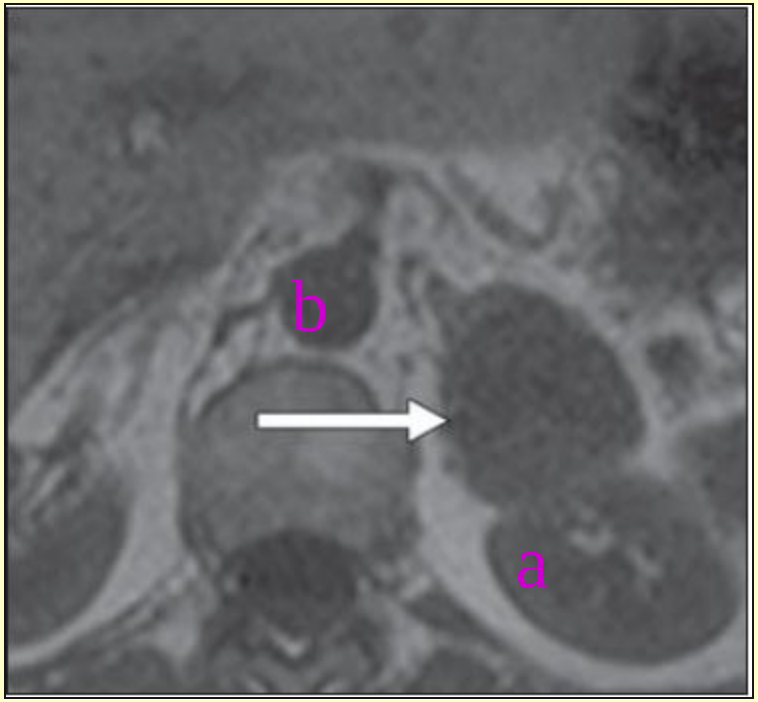

Axial T1-weighted shows low signal intensity left adrenal pheochromocytoma.
(white arrow). **a – kidney, b- aorta**

Example Companion 5

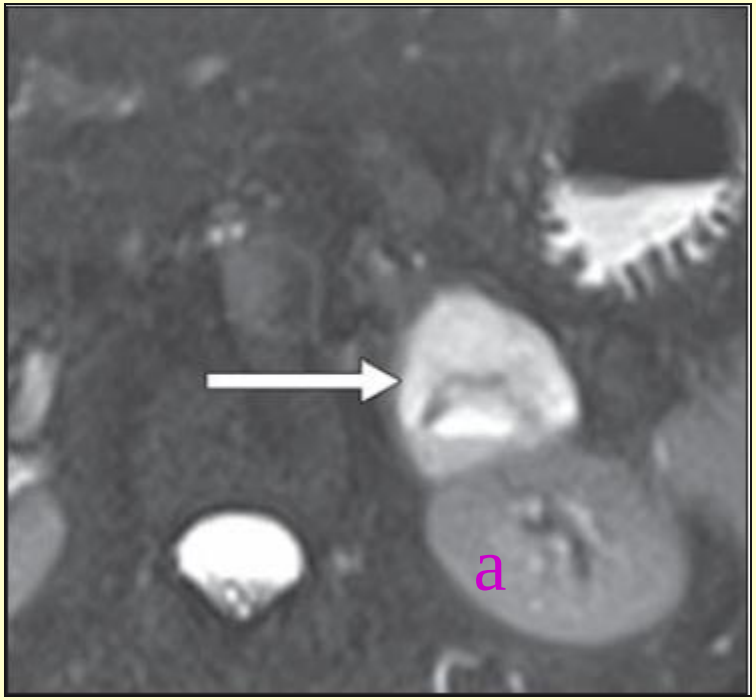

Axial fat suppressed T-2 weighted image showing "light bulb" right tumor (high T2 signal intensity). **a – kidney**

Images from Leung, K, Stamm, M, Raja, A, Low, G. Pheochromocytoma: The Range of Appearances on Ultrasound, CT, MRI, and Functional Imaging. *AJR* 2013; 200:370-378

Samuel Kim, HMSIII
Gillian Lieberman, MD

Features of Pheochromocytoma on Functional Imaging

- ^{131}I- and ^{123}I-metaiodobenzylguanidine (MIBG) most commonly used. MIBG is a norepinephrine analog that localizes to presynaptic adrenergic nerves and sympathomedullary tissue. Uptake of radiotracer is proportional to number of neurosecretory granules within tumor
- Pheochromocytomas will generally show unilateral focal uptake within tumor. Lower sensitivity than other tests, but high specificity. Useful test if concern for metastasis or unclear CT, MRI results
- Can often with combined with chemotherapy to target metastasis but has side effect of bone marrow suppression. Treatment may include cyclophosphamide, vincristine, dacarbazine.

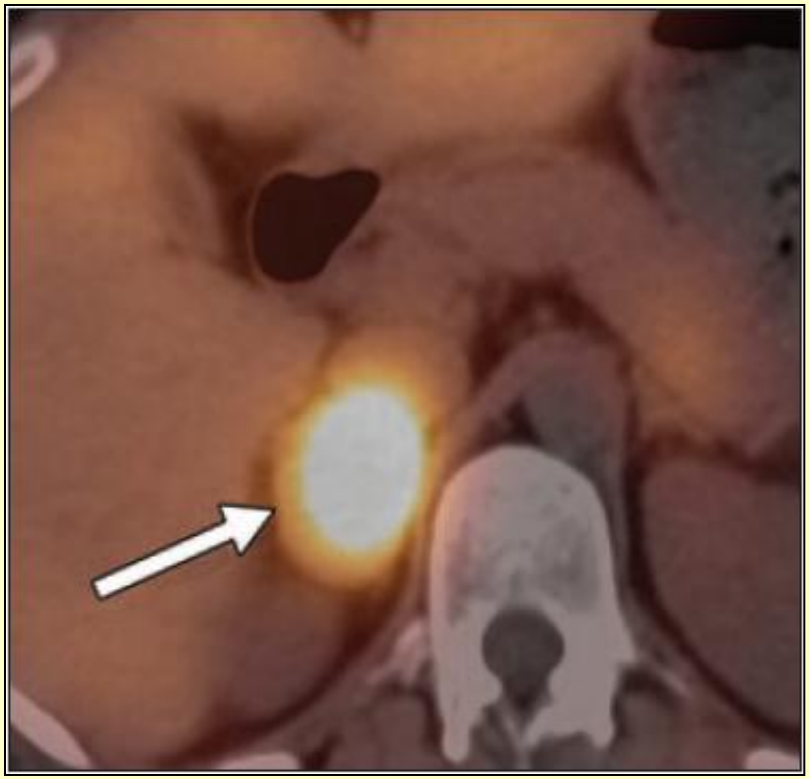

Example Companion 6: Axial ^{123}-MIBG fused CT image with radioisotracer uptake in the right adrenal tumor (white arrow)

Images from Leung, K, Stamm, M, Raja, A, Low, G. Pheochromocytoma: The Range of Appearances on Ultrasound, CT, MRI, and Functional Imaging. *AJR* 2013; 200:370-378

Samuel Kim, HMSIII
Gillian Lieberman, MD

Imaging Summary

- Pheochromocytomas can have variable appearance on imaging scan. They can have calcification, necrosis, fibrosis, cystic degeneration, intracellular lipid degeneration.
- As a rule of thumb: 10% bilateral, 10% extraadrenal, 10% malignant, 10% hereditary, 10% nonfunctioning. Diagnosis is usually suspected in young patient who presents with paroxysmal palpitations and hypertension
- CT scan analysis is primarily dependent on attenuation. Most pheochromocytomas will have unenhanced attenuation greater than 10H.
- CT with contrast with result in rapidly and avidly enhancing lesion with greater than 40H
- MRI: In general, low signal intensity on T1 and high intensity on T2. Usually will enhance intensely on T2, but may mimic adenoma if they contain fat.
- If CT, MRI not decisive, nuclear imaging, usually MIGB, can be used.

Samuel Kim, HMSIII
Gillian Lieberman, MD

Our Patient: Follow Up

- Patient treated preoperatively with alpha and beta blockade. She underwent left open adrenalectomy given patient's symptoms, substantially elevated catecholamines, and enlarging adrenal mass on imaging studies.

- Pathology consistent with pheochromocytoma with organizing hematoma (9 cm including the hematoma) with foci suspicious but not diagnostic for vascular invasion. No tumor necrosis, capsular invasion, or significant nuclear pleomorphism.

- Patient continued to show down trending urinary and plasma catecholamines on subsequent visits. Patient improved symptomatically as well.

References

- **Leung, K, Stamm, M, Raja, A, Low, G. Pheochromocytoma: The Range of Appearances on Ultrasound, CT, MRI, and Functional Imaging. *AJR* 2013; 200:370-378**
- **Chew, FS, Banks, KP. Imaging of Pheochromocytoma and Incidental Adrenal Lesions: Self-Assessment Modules. *AJR* 2006; S467-469**
- **rr, RD, Hofbauer, LC, Naumann, B, Borstein, SR, Eisenhofer, G. Pheochromocytoma –update on disease management. *Therapuetic Advances in Endocrinology and Metabolism* 2012; 3(1): 11-26**
- **Blake MA, Cronin, CG, GW, Boland. Adrenal Imaging. *AJR* 2010; 194(6):1450-60**
- **Young, WF. The Incidentally Discovered Adrenal Mass. *New England Journal of Medicine* 2007; 356:601-610**
- **Eisenhofer, G, Goldstein, DS, McClellan, MW, Friberg, P, Lenders, JWM, Keiser, HR, Pacak, K. Biochemical Diagnosis of Pheochromocytoma: How to Distinguish True from False Positive Test Results. *The Journal of Clinical Endocrinology and Metabolism* 2003. 88(6): 2656**

Acknowledgements

Monica Agarwal, MD

Gillian Lieberman, MD

Claire Odom

Core and Advanced Radiology Clerkship